




**Smaller! Faster! More!**  
 Advanced X-Ray Breast Imaging  
 and its Role Beyond Cancer Diagnosis

**Ioannis Sechopoulos, PhD, DABR, FAAPM**  
 Chair, Advanced X-ray Tomographic Imaging (AXTI) Lab  
 Department of Radiology and Nuclear Medicine  
 Radboud University Medical Center  
 and  
 Dutch Expert Center for Screening (LRCB)

ioannis.sechopoulos  
 @radboudumc.nl  
 axti.radboudimaging.nl  
 ioannisNL









1

**AXTI Lab**  
 (Advanced X-ray  
 Tomographic Imaging -  
 "Action" in Dutch)

Ritse Mann  
 Ewoud Smit  
 Many breast radiologists




James Nagy  
 Marc Kachelriess

2

**Disclosures**

Research Agreement, Siemens Healthcare  
 Research Agreement, Canon Medical Systems  
 Speaking Agreement, Siemens Healthcare


3






4

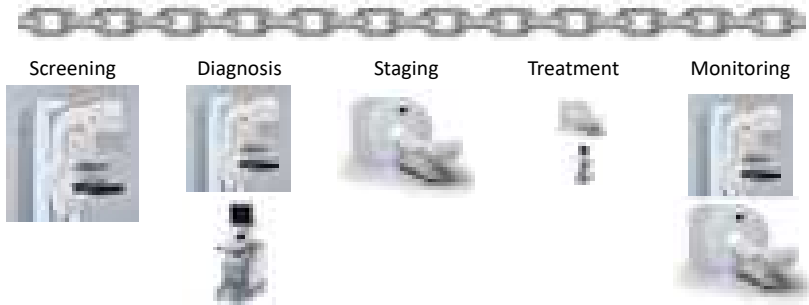
# The old imaging chain...



<http://apachetechnology.in/KC/Multimedia/DIP/Medical/DigitalXRay.aspx>

5


# ...the breast cancer care chain




6

# SCREENING

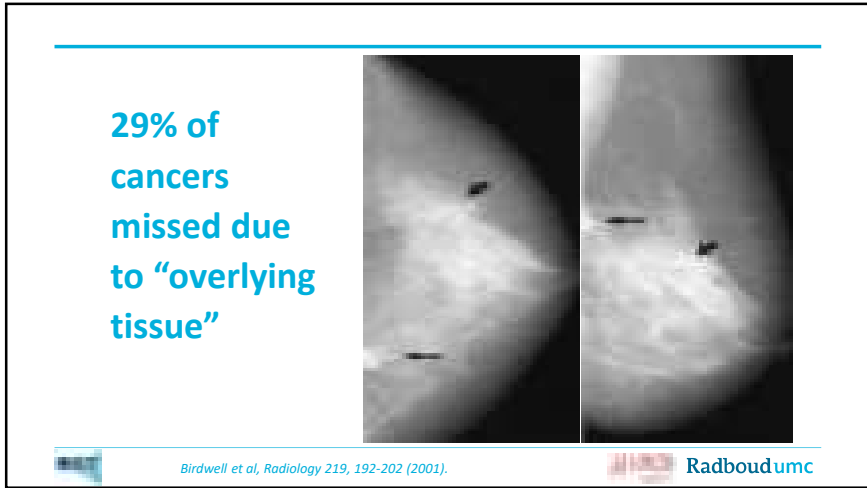7



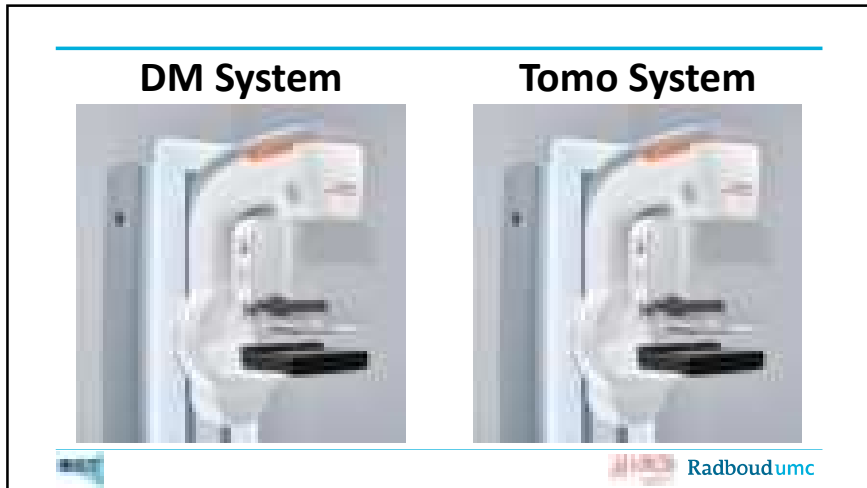
8



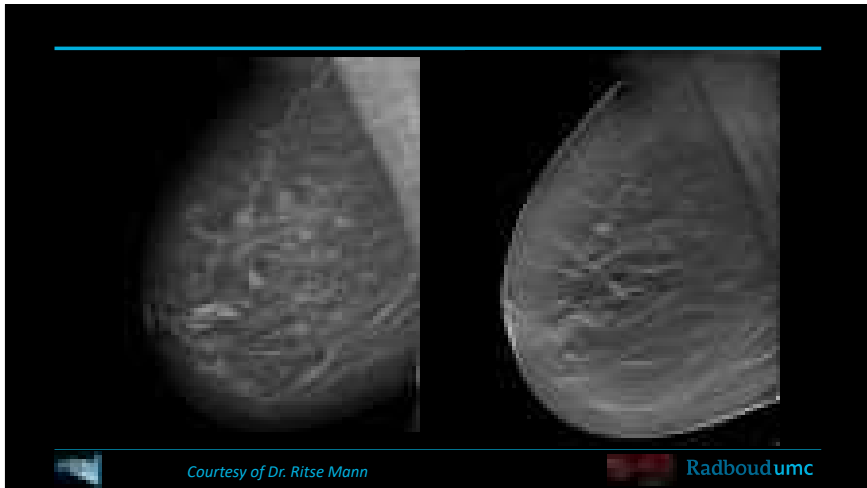9



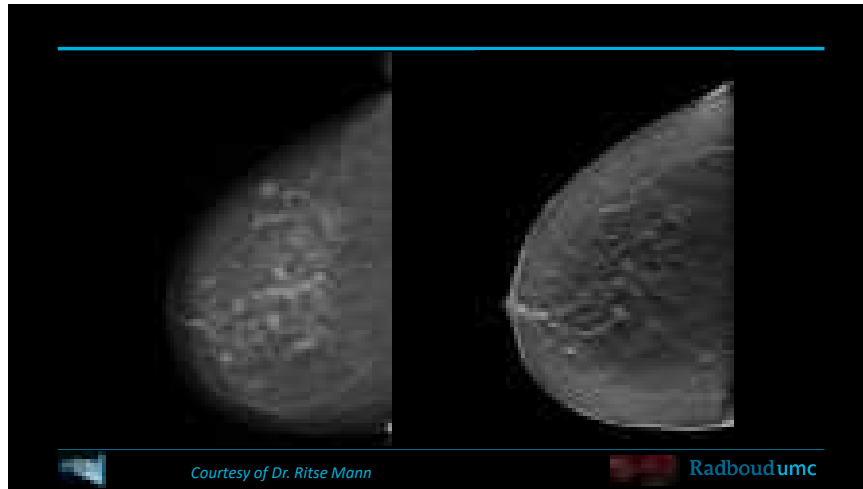10



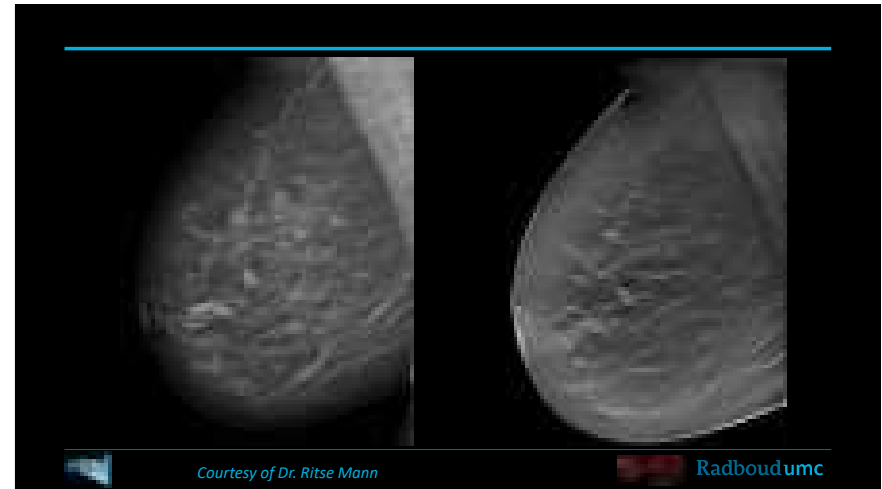11



12



13



14

## Benefits of tomosynthesis

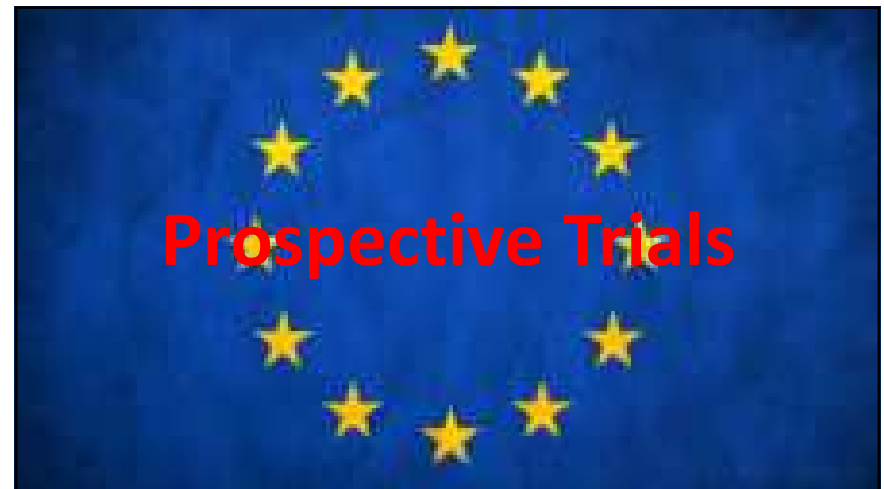Mammography++

- System
- Workflow
- Interpretation
- Dose

...but with **some** discrimination of vertical position!

Radboudumc

15



16

## MLO-view DBT only – Malmö

Number of Participants	Cancer Detection Change	Recall Rate Change
14,848	6.5‰ → 8.7‰	2.5% → 3.6%
	+34%	+44%

Zackrisson et al, Lancet Oncology, October 2018.

 Radboudumc

17

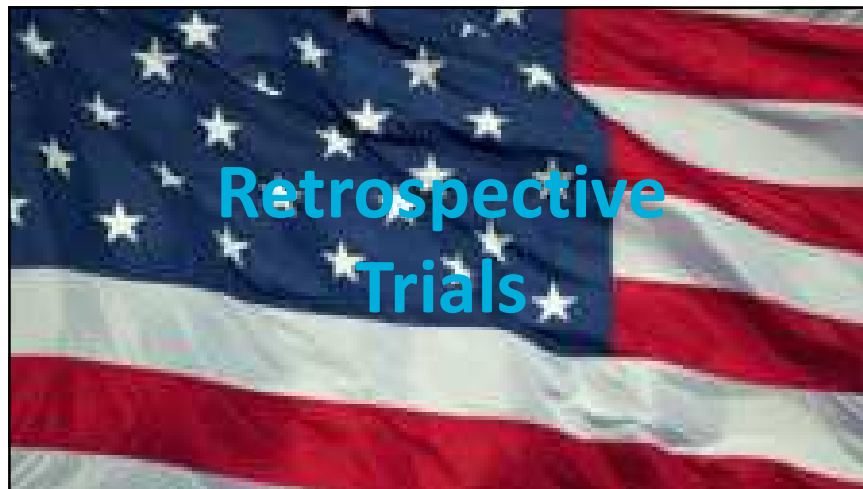## Single Reading DM+DBT – STORM

Number of Cases	Cancer Detection Change	Recall Rate Change
7,292	5.3‰ → 7.5‰	4.9% → 3.6%
	+41.5%	-26.5%

Houssami et al, European Journal of Cancer, 2014

 Radboudumc

18



19

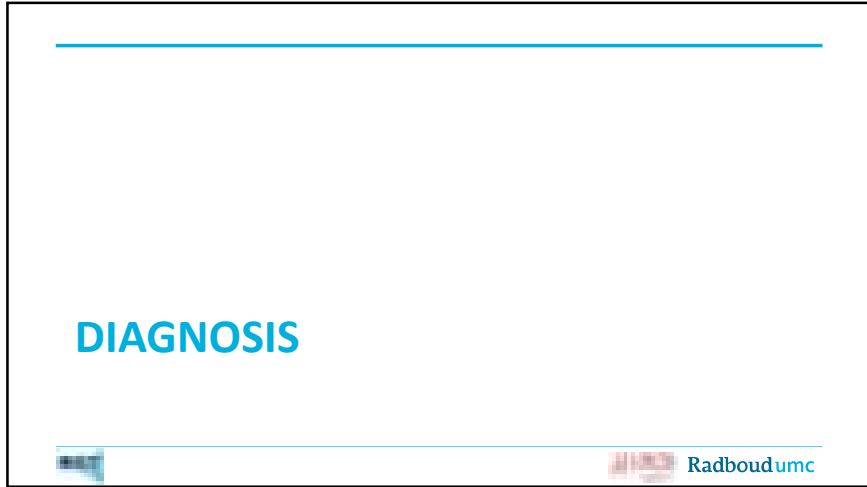
## Retrospective - USA

Exams	Women	Cancer Det Rate per recall	Recall Rate
44,468	23,958	4.4% → 6.2-6.7%	10.4% → 8.8-9.2%
		+46.6%	-13.5%

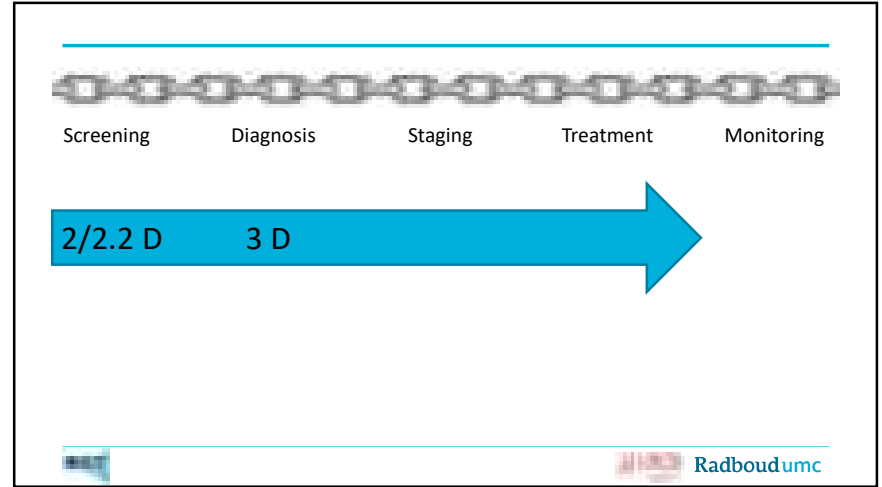
McDonald et al, JAMA Oncol. 2016;2(6):737-743

 Radboudumc

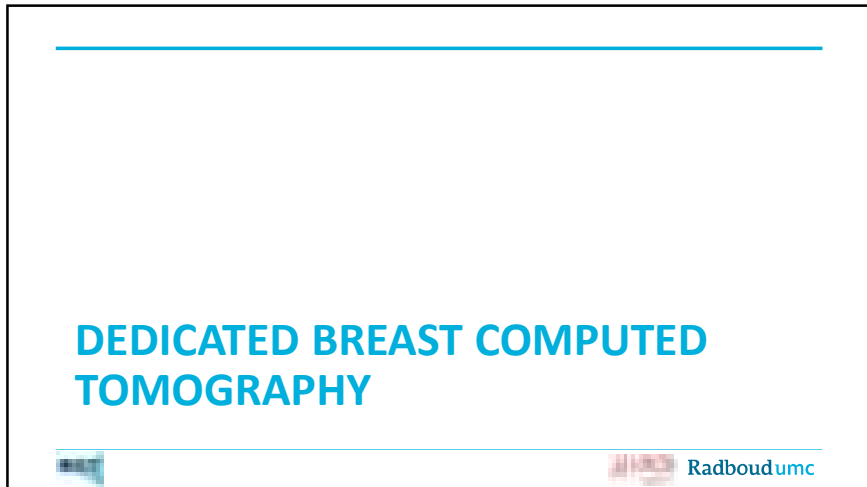
20



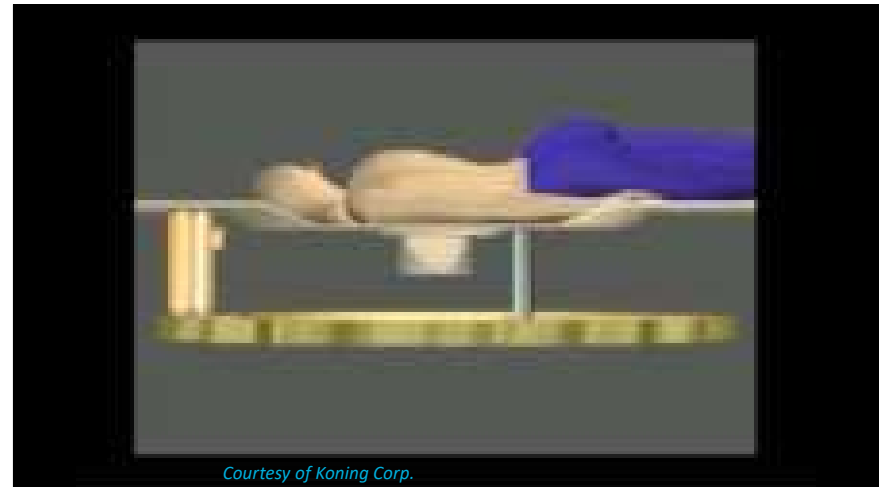
21



22



23



24




25



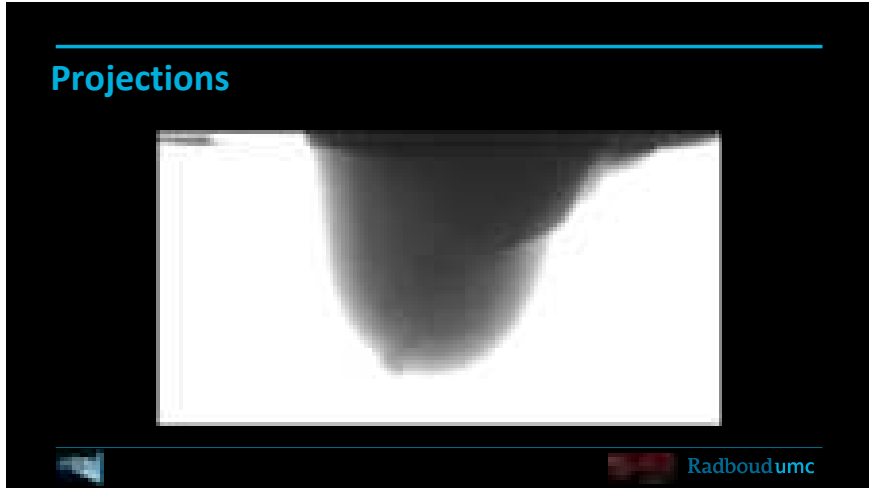
26




27



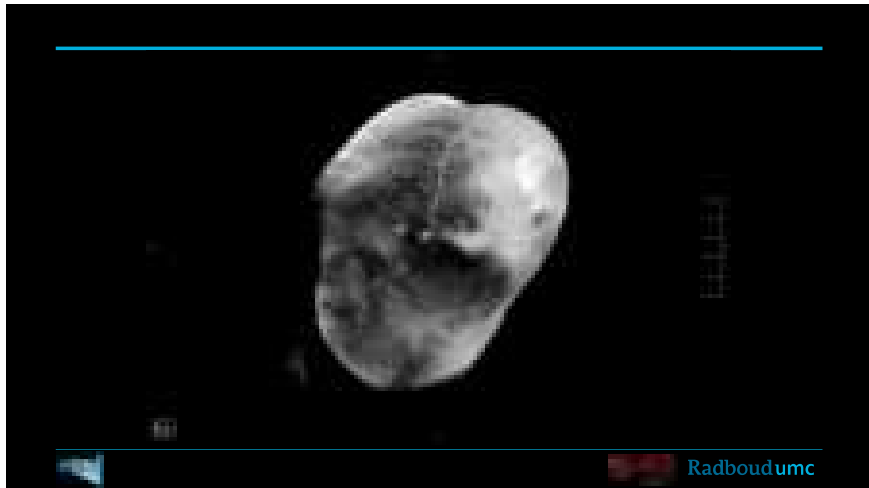
28



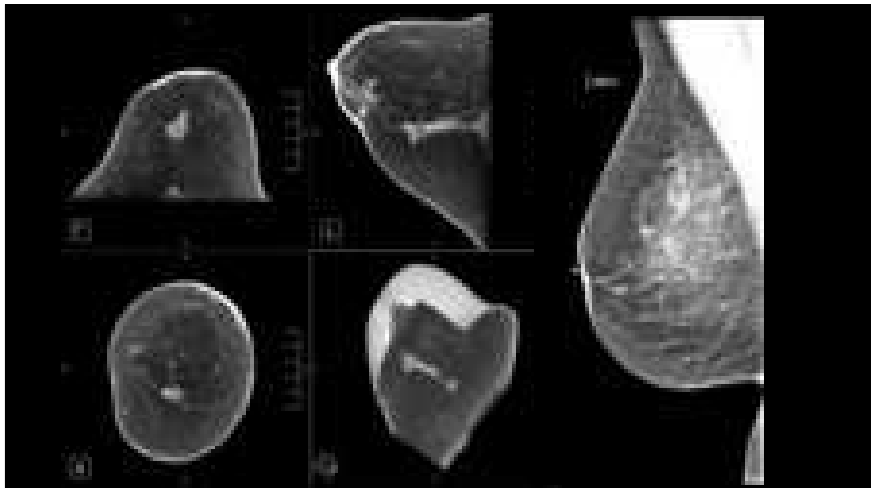
29



30

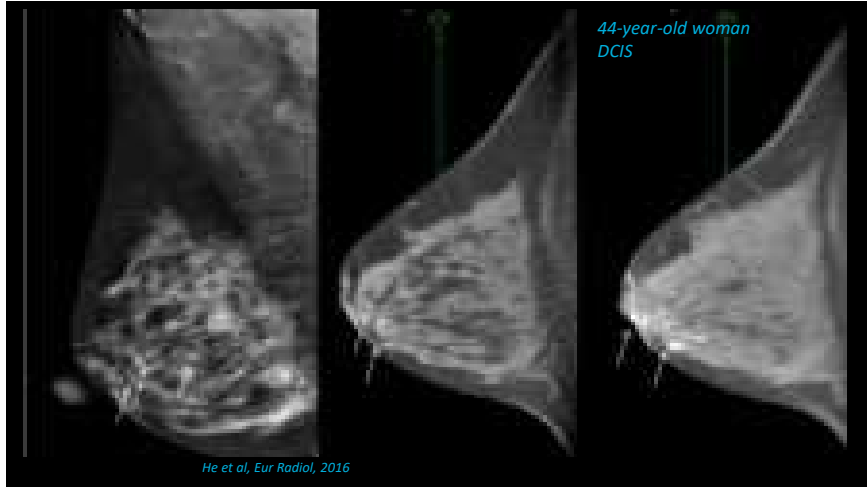

31

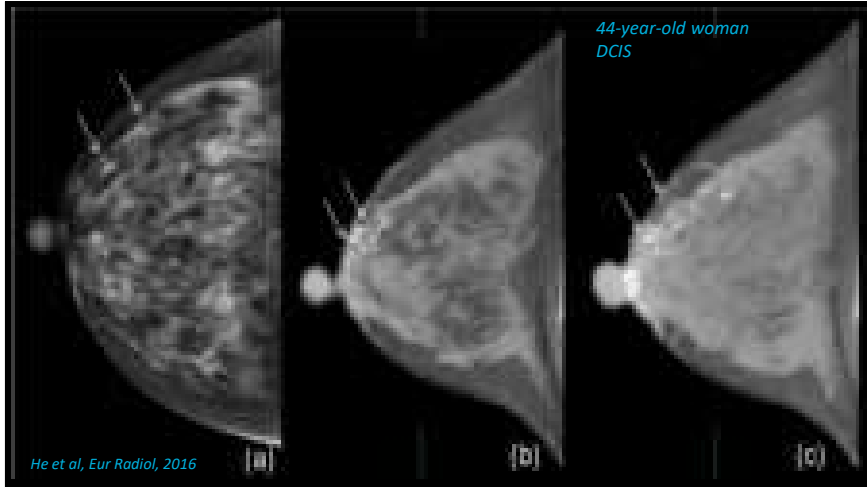


32





33



34

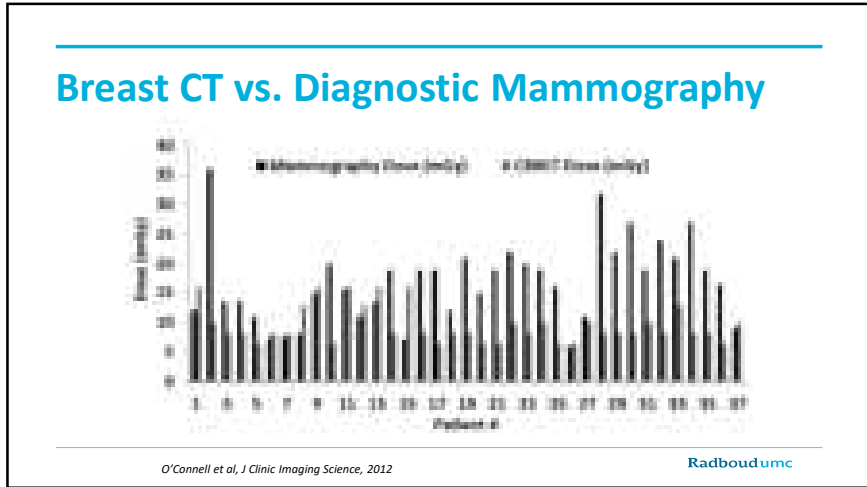
**RADIATION DOSE**

35

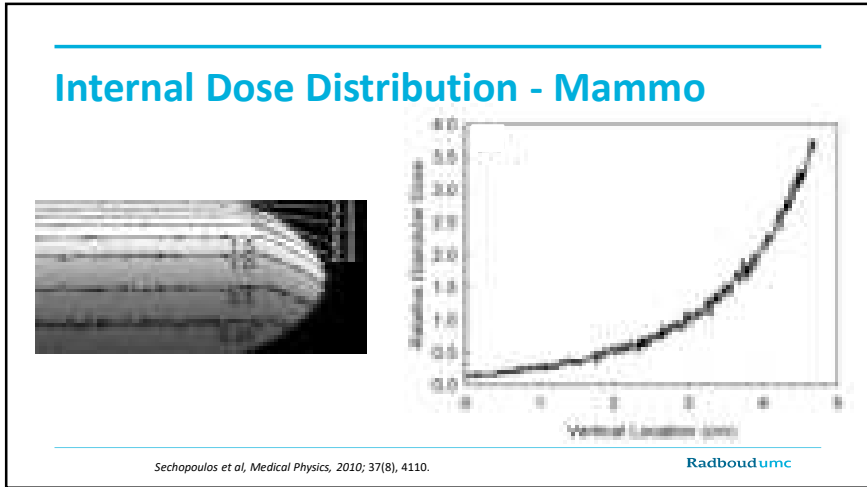
**Breast CT vs. Diagnostic Mammography**

Sechopoulos et al, Medical Physics, 2010; 37(8), 4110.

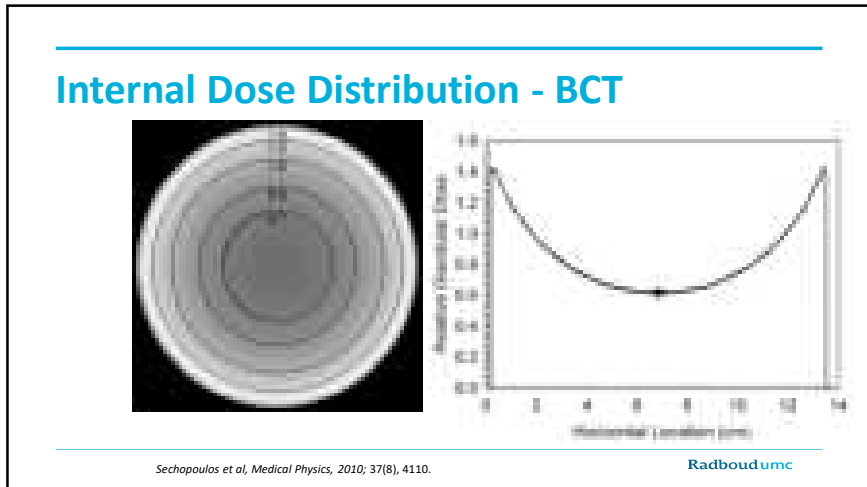
36



37



38



39

### SPLIT-SPECTRUM IMAGING

Radboudumc

40

## Polychromatic forward model

$$\hat{p}_i(\vec{u}^T) = \sum_n b_{in} \exp \left( - \sum_m \mu_m^{(n)} \sum_j l_{ij} w_{mj} \right)$$

Bustamante et al., SIAM J. Sci. Comput. 35(5), 2013.

Radboudumc

41

## Polychromatic forward model

$$\hat{p}_i(\vec{u}^T) = \sum_n b_{in} \exp \left( - \sum_m \mu_m^{(n)} \sum_j l_{ij} w_{mj} \right)$$



Glandular

Adipose

Bustamante et al., SIAM J. Sci. Comput. 35(5), 2013.

Radboudumc

42

## Polychromatic forward model

$$\hat{p}_i(\vec{u}^T) = \sum_n b_{in} \exp \left( - \sum_m \mu_m^{(n)} \sum_j l_{ij} w_{mj} \right)$$



Bustamante et al., SIAM J. Sci. Comput. 35(5), 2013.

Radboudumc

43

## Polychromatic forward model

$$\hat{p}_i(\vec{u}^T) = \sum_n b_{in} \exp \left( - \sum_m \mu_m^{(n)} \sum_j l_{ij} w_{mj} \right)$$



Bustamante et al., SIAM J. Sci. Comput. 35(5), 2013.

Radboudumc

44

## Polychromatic forward model

$$\hat{p}_i(\vec{u}^T) = \sum_{\omega} b_{i\omega} \exp\left(-\sum_{\mu} \mu_{\omega}^{(\mu)} \sum_j l_{ij} w_{\omega j}\right)$$



W/Al (1.5 mm) + Cu (0.254 mm)


*Bustamante et al., SIAM J. Sci. Comput. 35(5), 2013.*

Radboudumc

45

## Polychromatic forward model

$$\hat{p}_i(\vec{u}^T) = \sum_{\omega} b_{i\omega} \exp\left(-\sum_{\mu} \mu_{\omega}^{(\mu)} \sum_j l_{ij} w_{\omega j}\right)$$

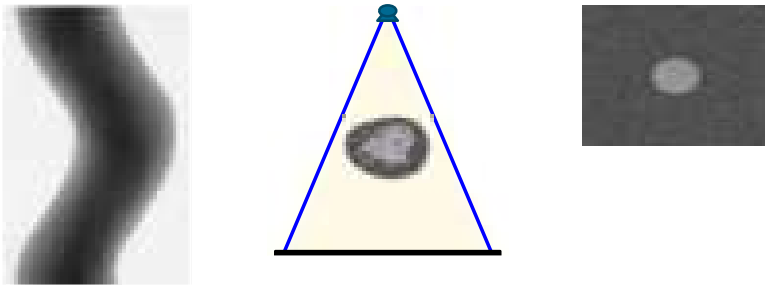


*Bustamante et al., SIAM J. Sci. Comput. 35(5), 2013.*

Radboudumc

46

## Acquisition Process

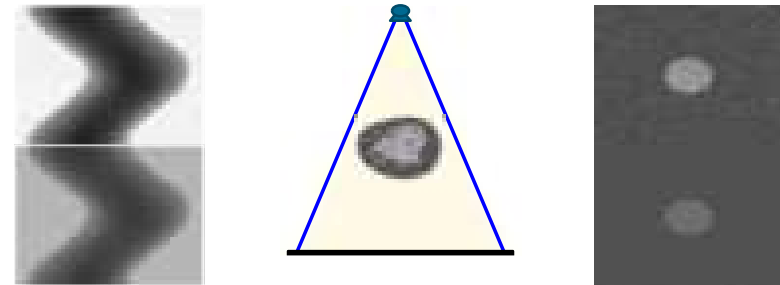


*Michielsen et al., IWBI 2018*

Radboudumc

47

## Acquisition Process



*Michielsen et al., IWBI 2018*

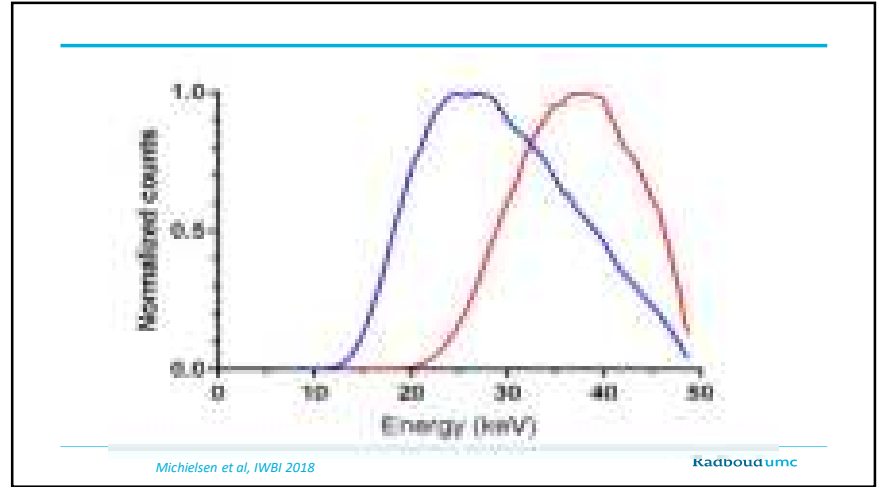
Radboudumc

48



Radboudumc

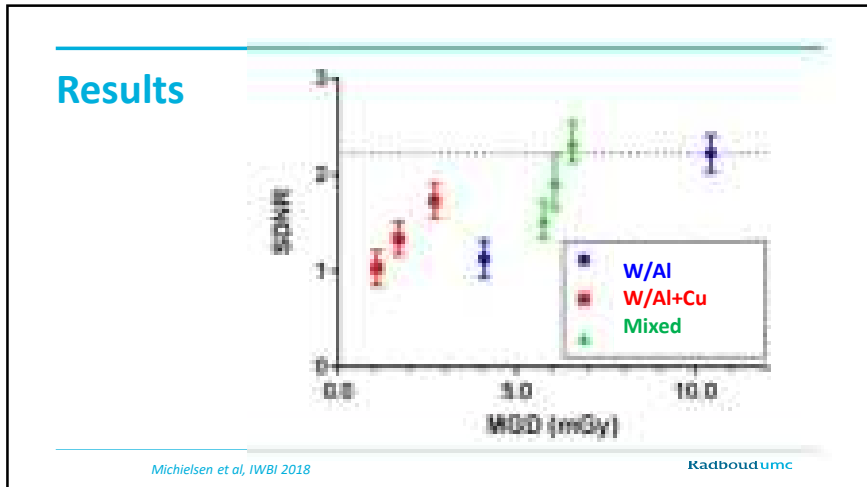
49



Michielsen et al, IWBI 2018

Radboudumc

50



Michielsen et al, IWBI 2018

Radboudumc

51

Can we get more out of the images?

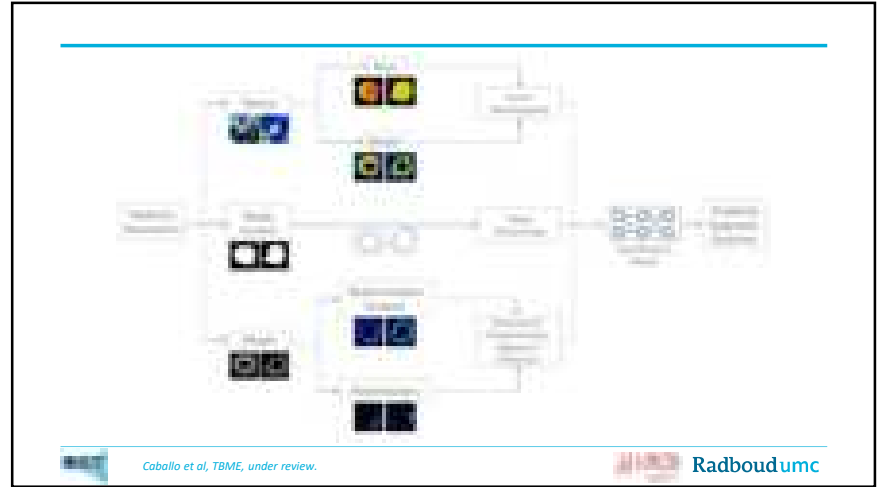
Radboudumc

52

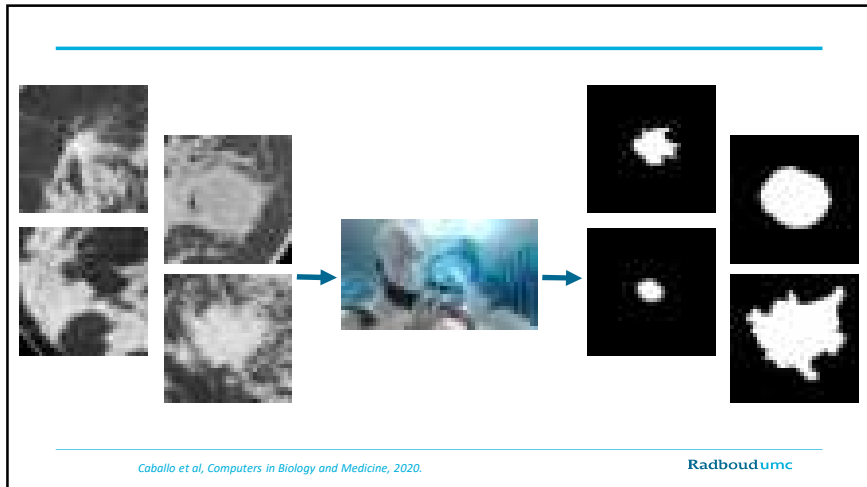
# RADIOMICS FOR BREAST CT MASS CHARACTERIZATION

Radboudumc

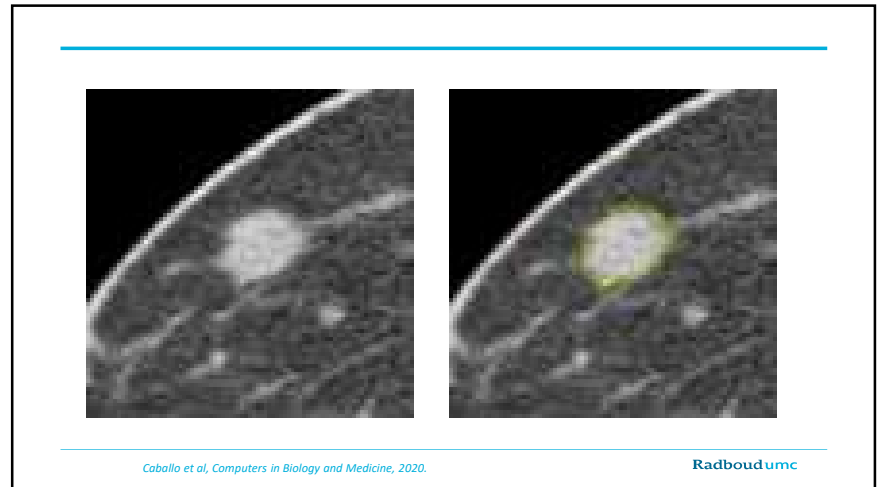
53



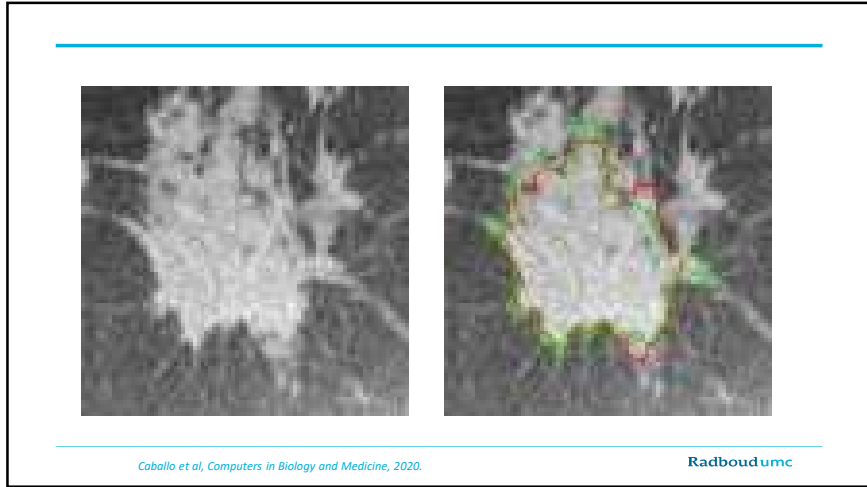
54



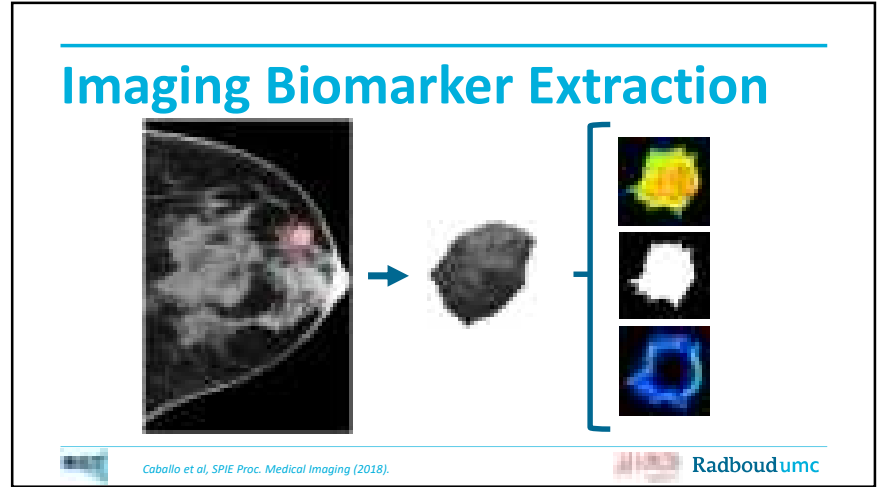
55



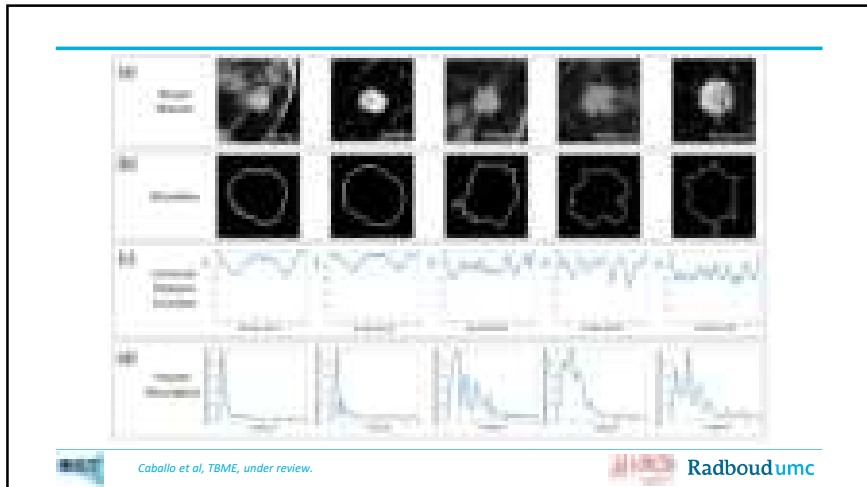
56



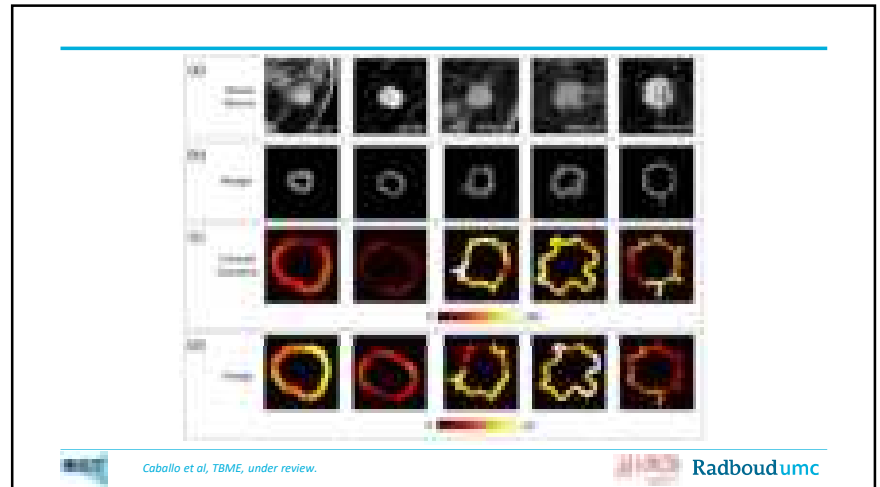
57



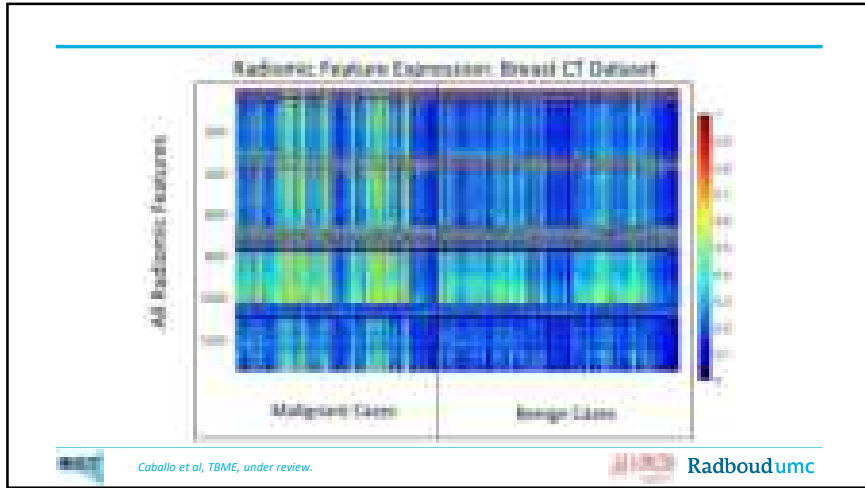
58



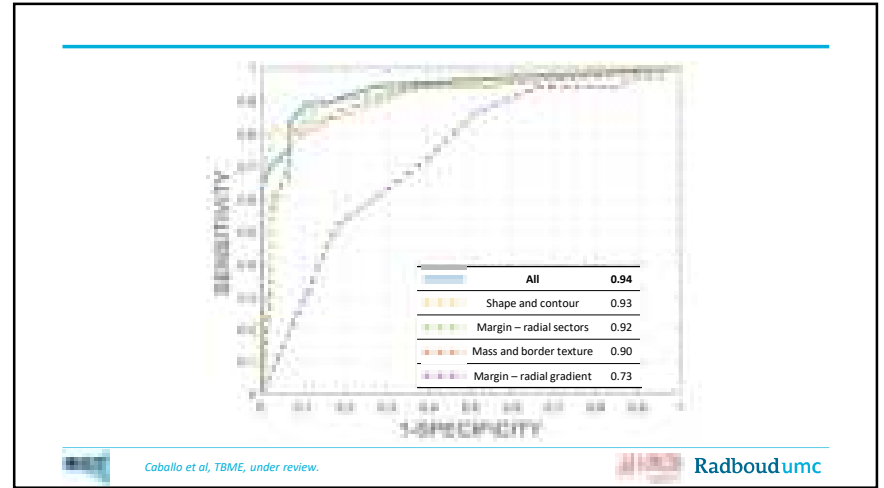
59



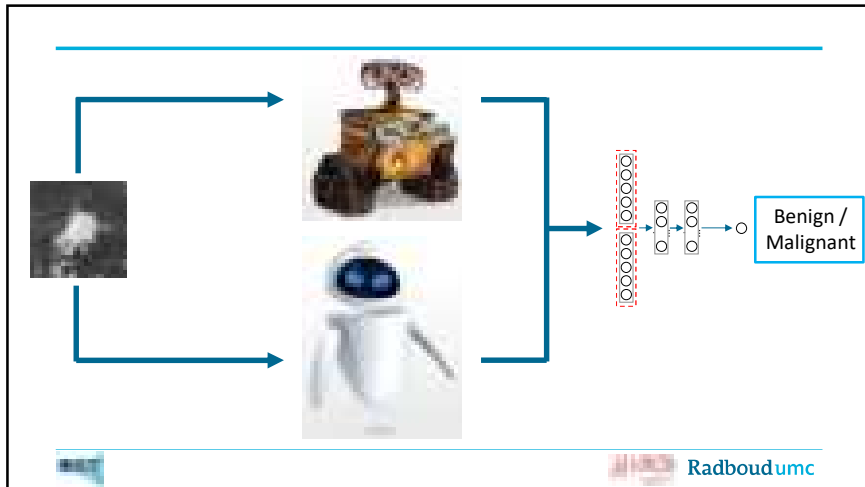
60



61



62




63

**STAGING & TREATMENT**


**Radboudumc**

64

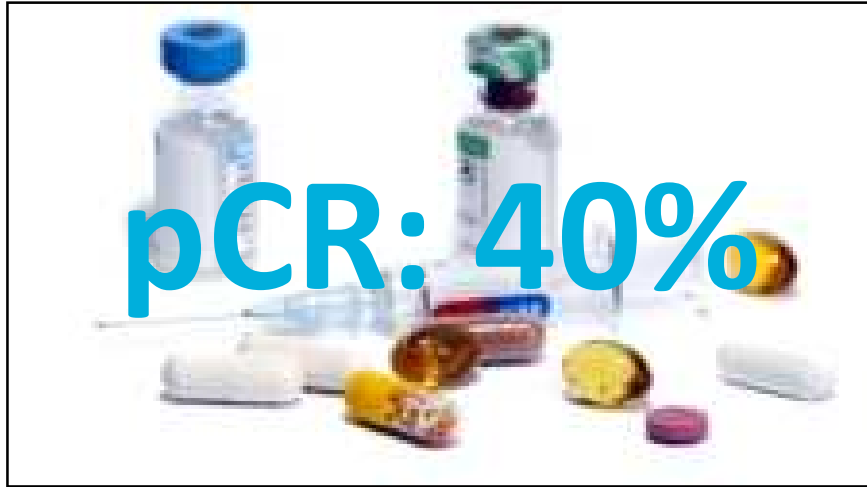



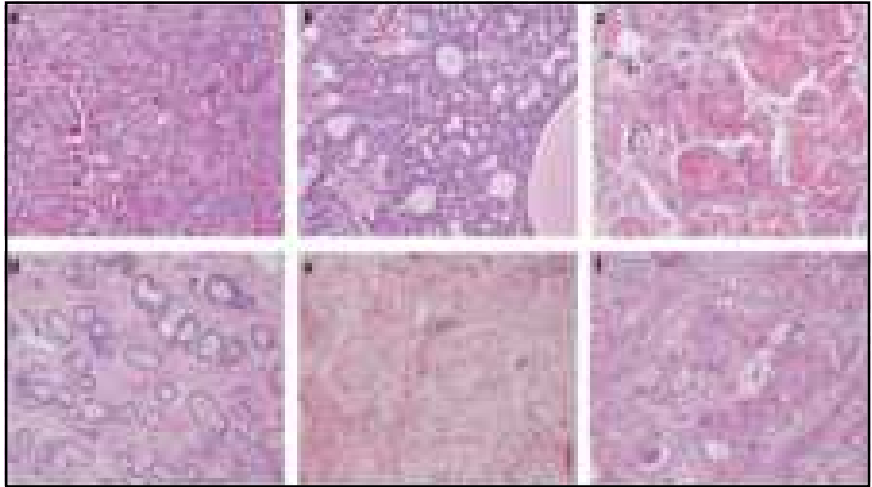
65



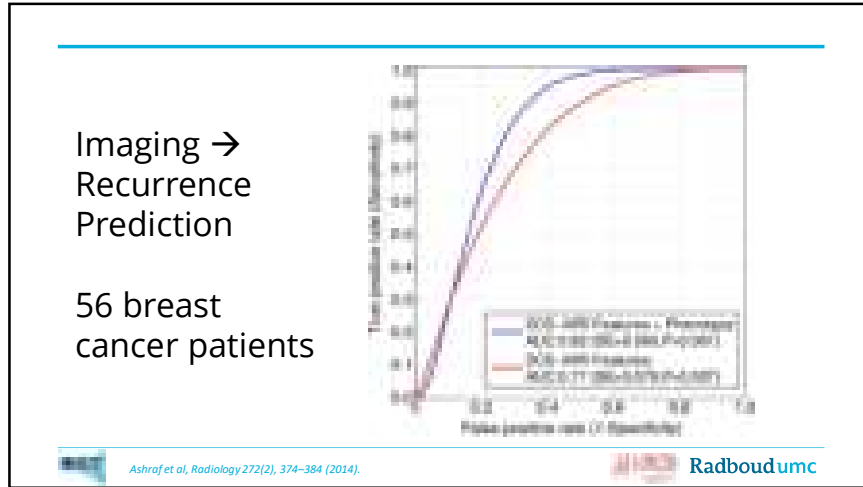
66



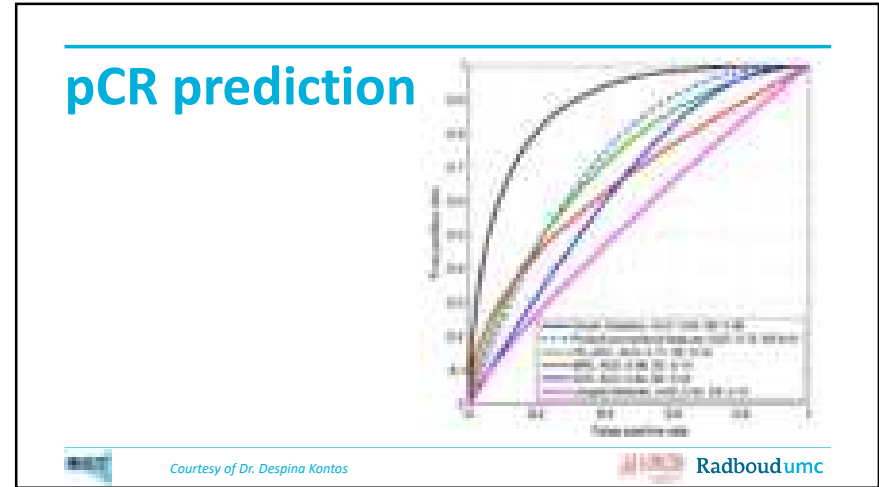
67



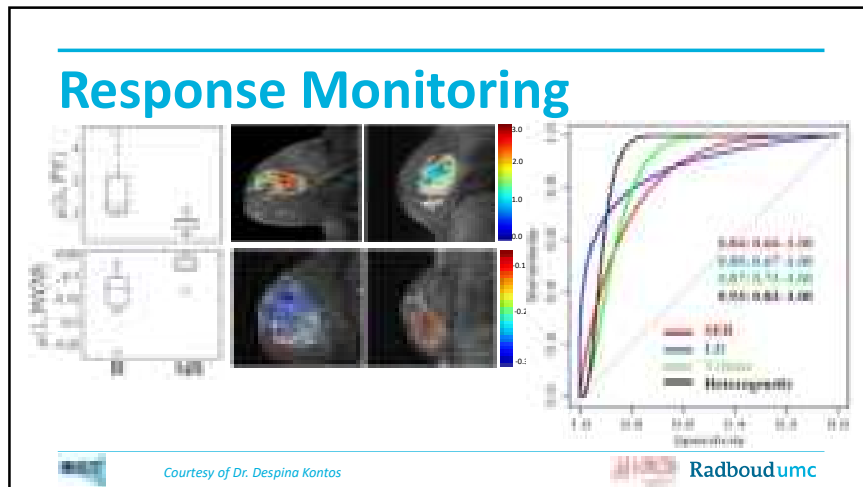
68



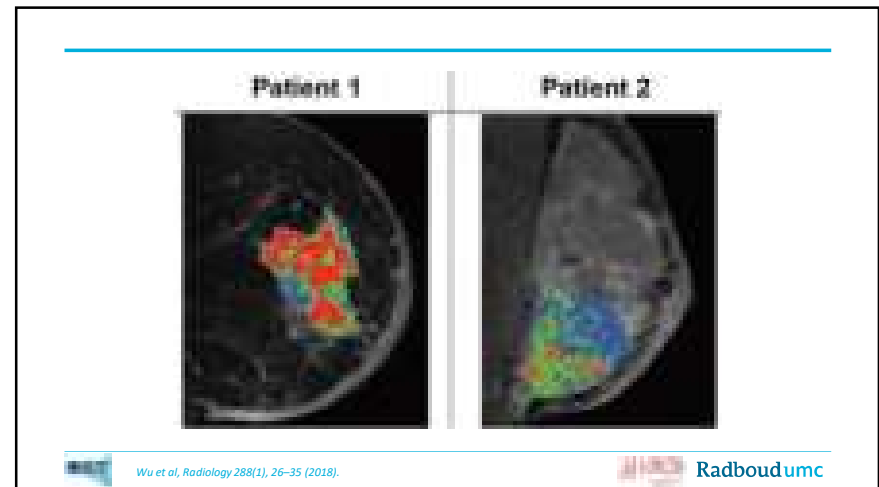
69



70



71



72

“Future work could incorporate ...imaging techniques with **higher temporal and spatial resolution**...in defining intratumoral subregions.”

Wu et al, Radiology 288(1), 26–35 (2018).

Radboudumc

73



2/2.2 D      3 D      4 D



Radboudumc

74

Dynamic Perfusion Dedicated Breast CT  
**4D BCT**

has the potential to provide  
functional imaging with  
very high spatial- and temporal resolution



Radboudumc

75

**4D Breast CT**

Technique optimization

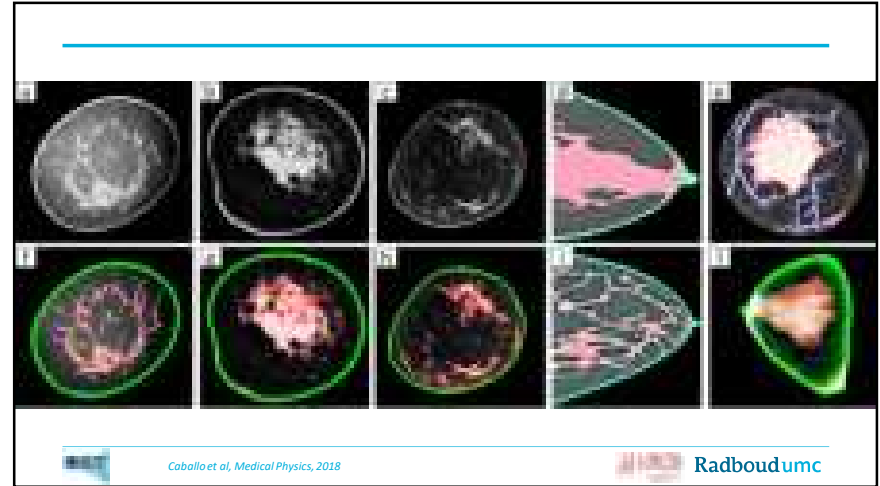


Radboudumc

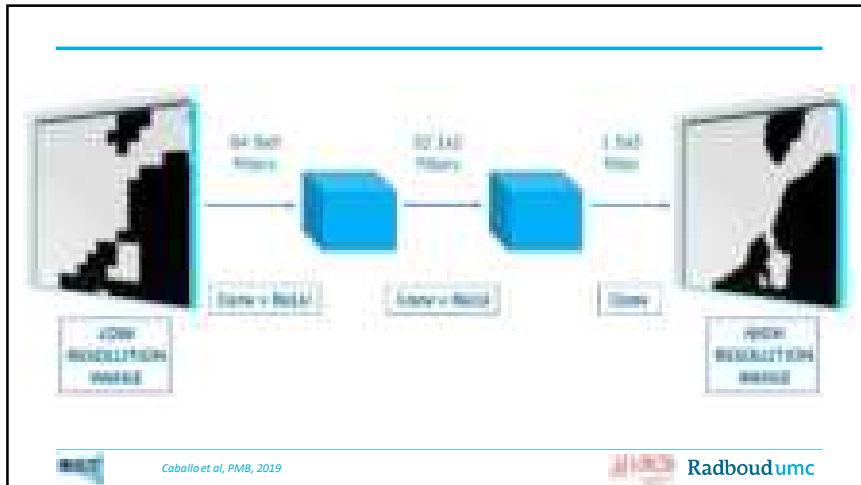
76

# 4D (software) breast phantom

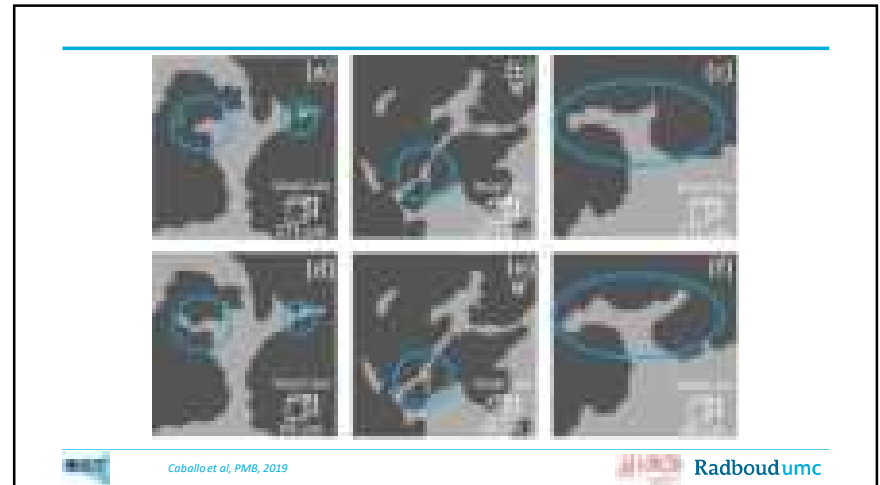
77



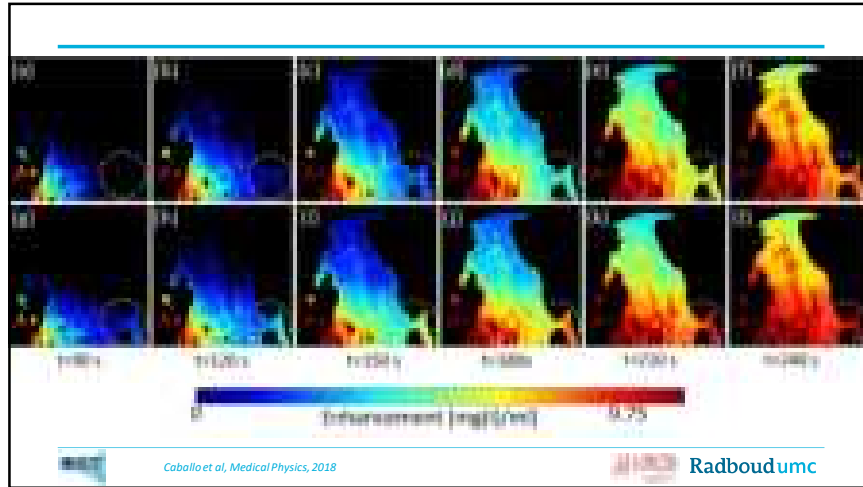
78



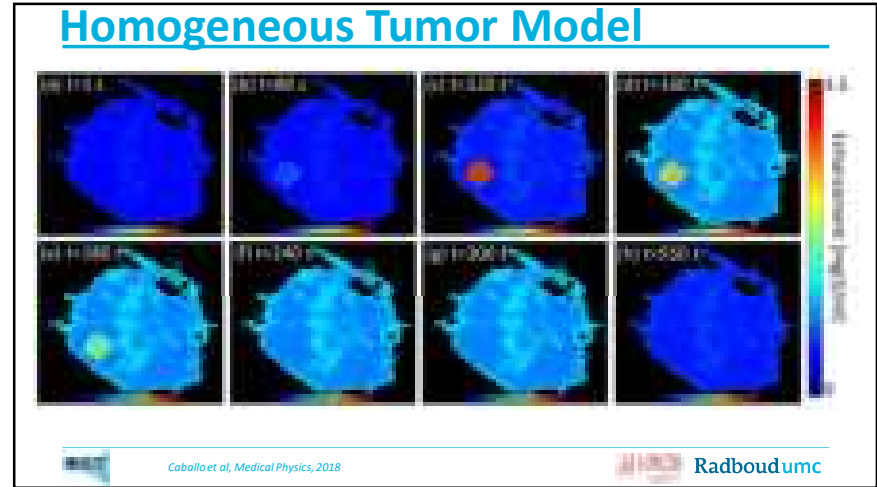
79



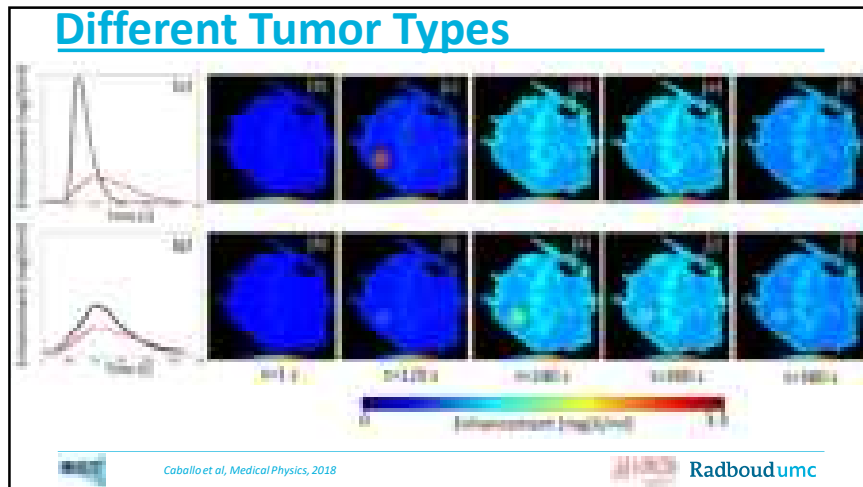
80




81



82



83



84

## 4D Breast Phantom



Caballo et al, Medical Physics, 2018

Radboudumc

85


## 4D breast CT (software) simulations

Radboudumc

Radboudumc

86

4D Breast Phantom

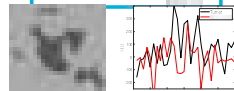


Ray Tracing

Scatter Estimate



Resolution Loss and Noise Model



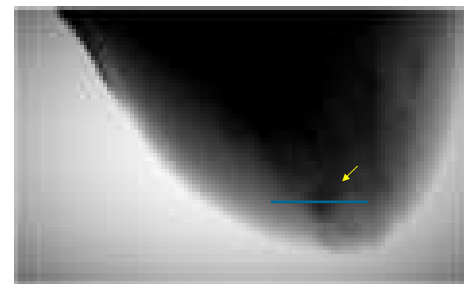
4D Simulated Image

Caballo et al, PMB, 2019

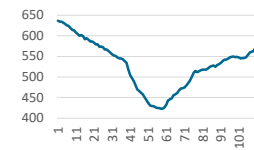Radboudumc

87

## Ray Tracing



Intensity Profile



Radboudumc

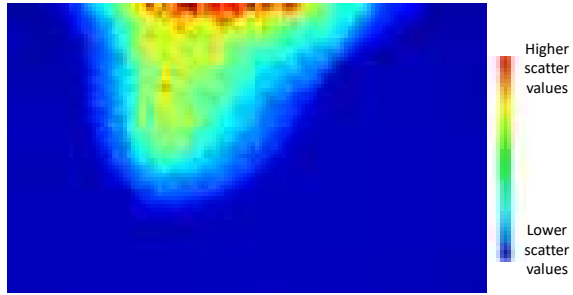
Caballo et al, PMB, 2019

Radboudumc

88

## Scatter Estimate

### Monte Carlo Simulations

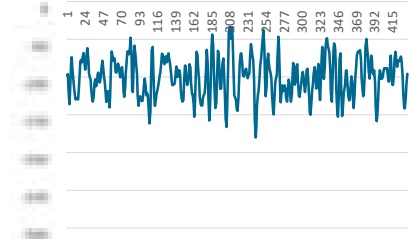



Caballo et al, PMB, 2019

Radboudumc

89

## Scatter-free

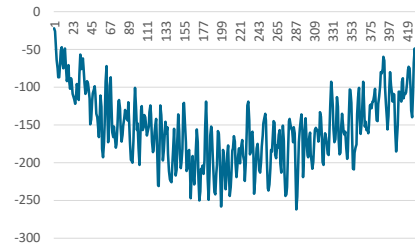
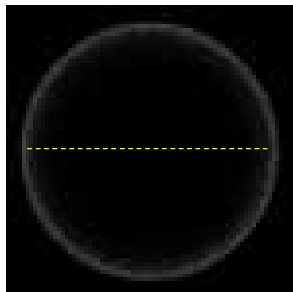


Caballo et al, PMB, 2019

Radboudumc

90

## Scatter



Caballo et al, PMB, 2019

Radboudumc

91

## Resolution Loss



Caballo et al, PMB, 2019

Radboudumc

92

## Resolution Loss

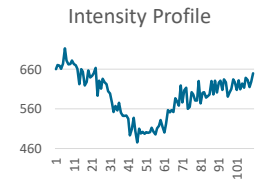
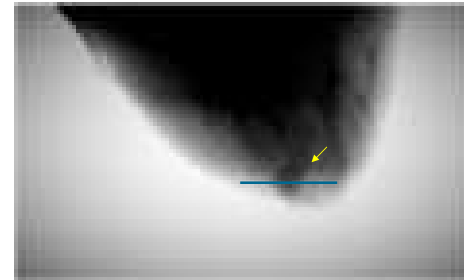


Caballo et al, PMB, 2019

Radboudumc

93

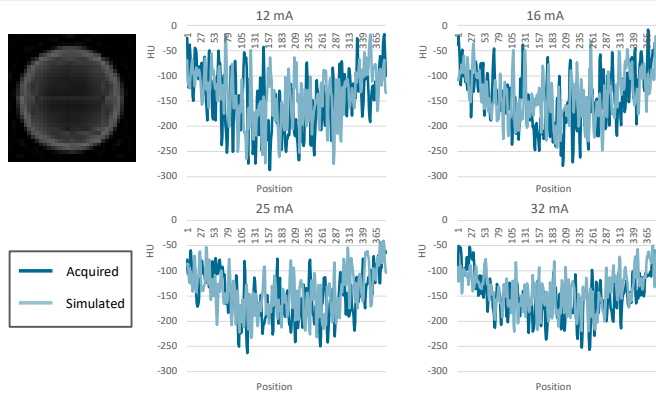
## Simulated projections



Caballo et al, PMB, 2019

Radboudumc

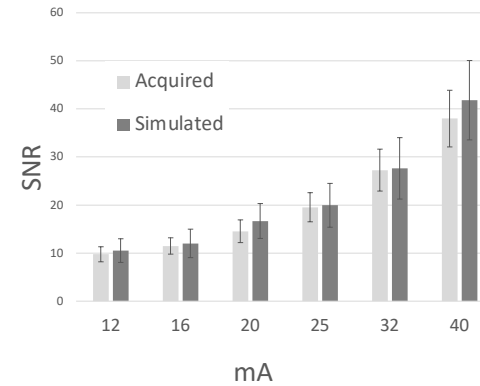
94



Caballo et al, PMB, 2019

Radboudumc

95

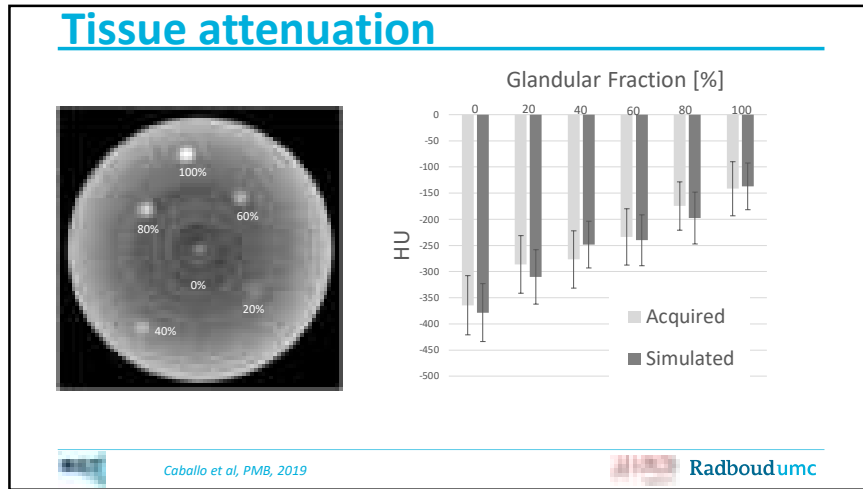


Caballo et al, PMB, 2019

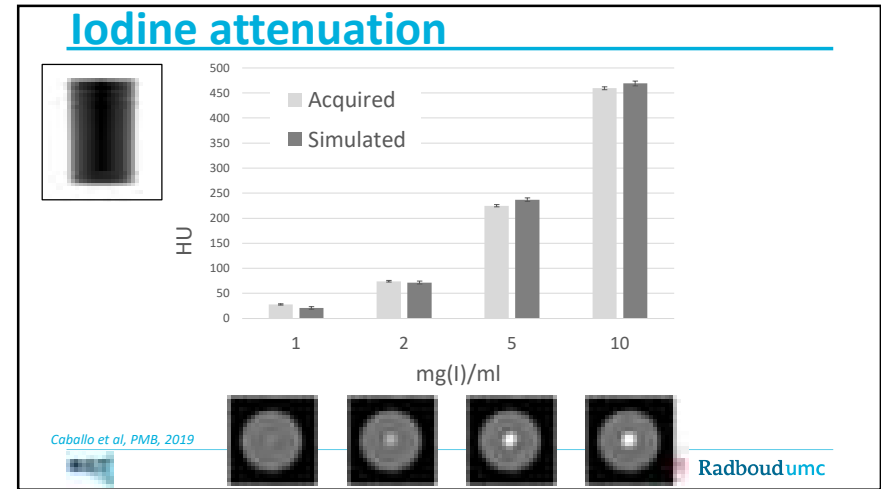
Radboudumc

96

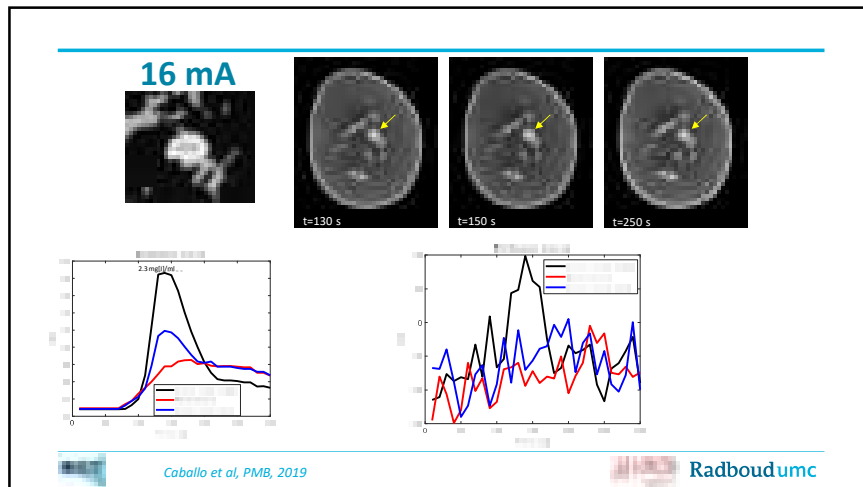




97



98

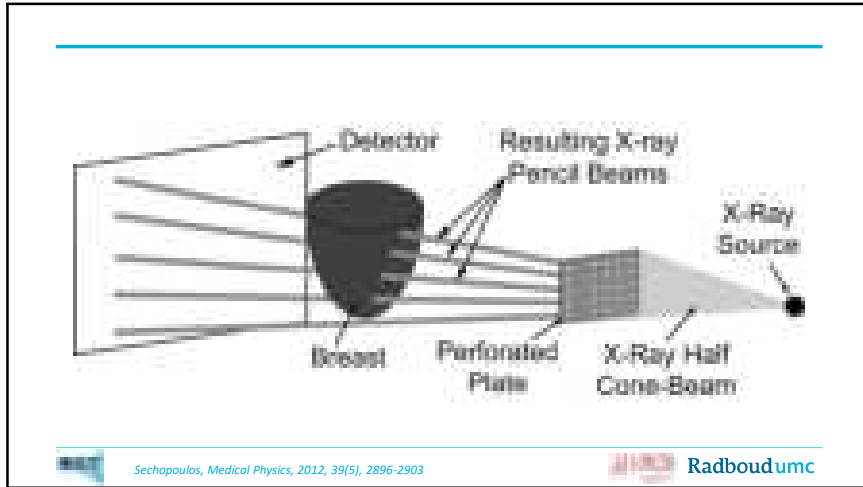


99

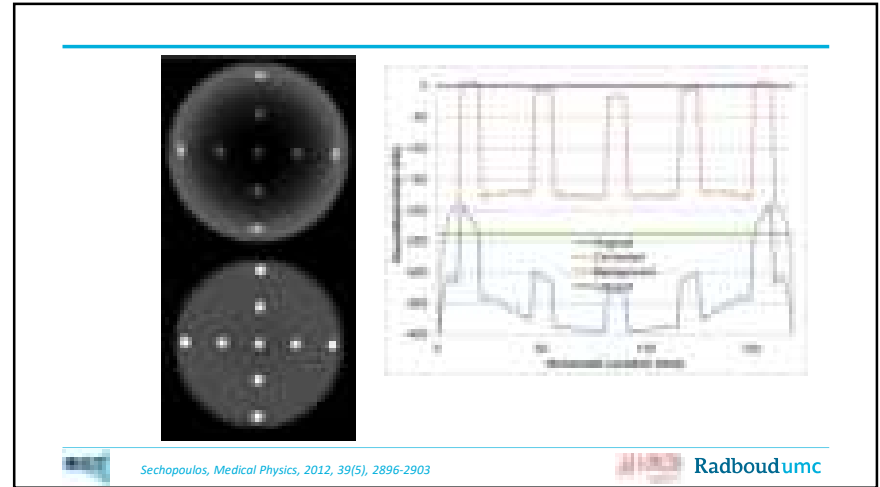
# 4D image correction algorithms

Radboudumc

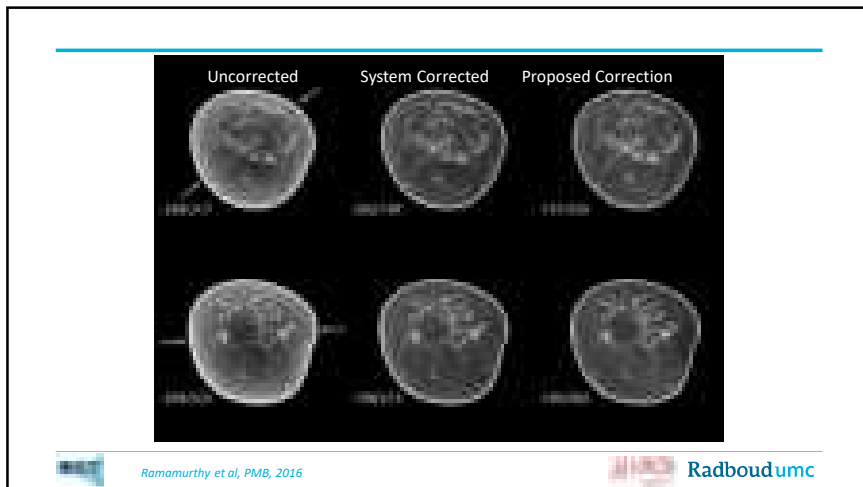
100



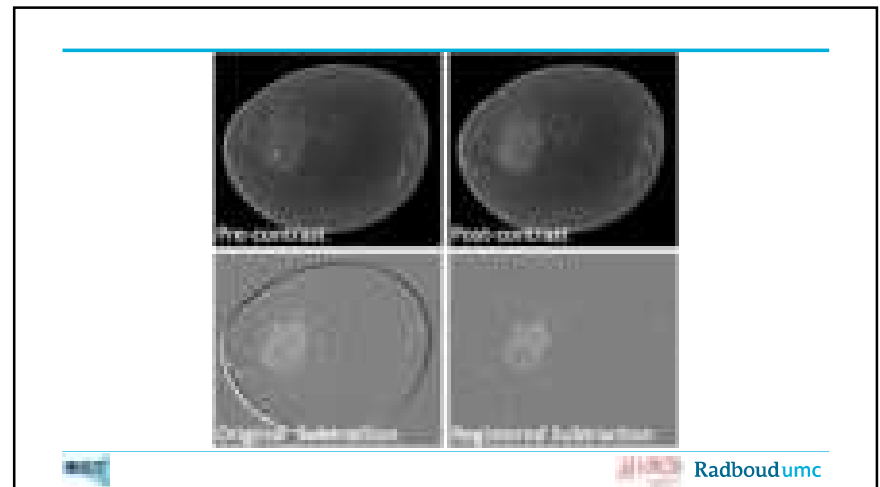
101



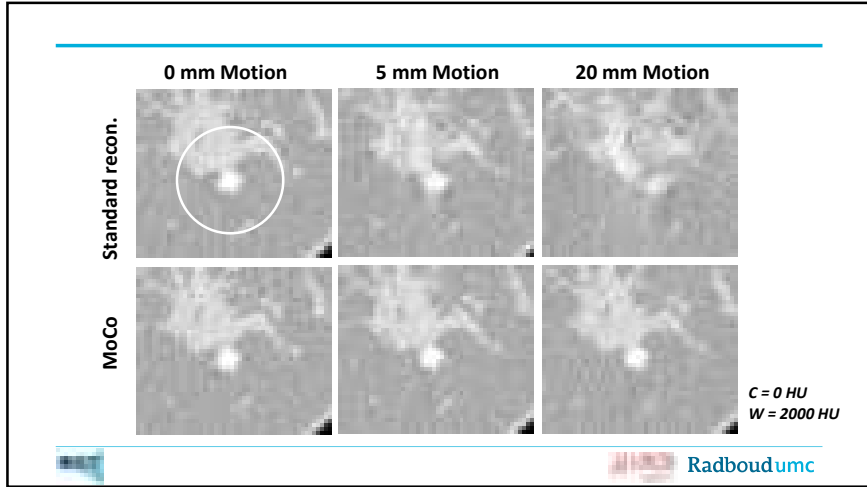
102



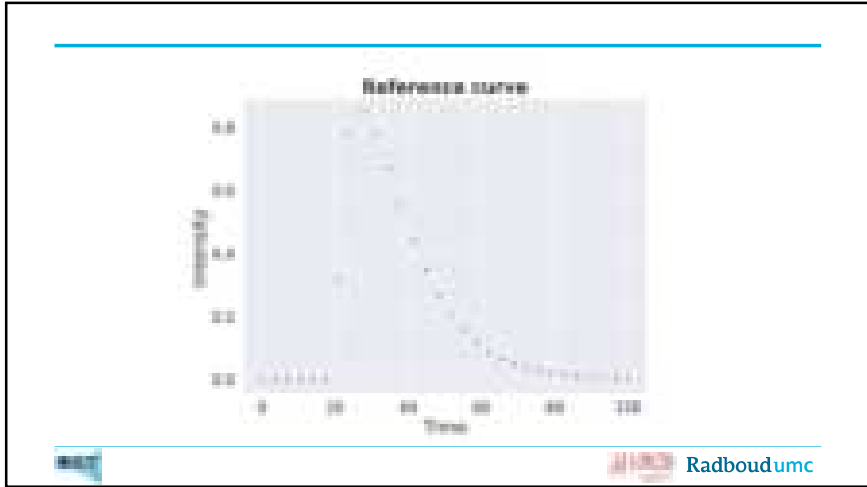
103



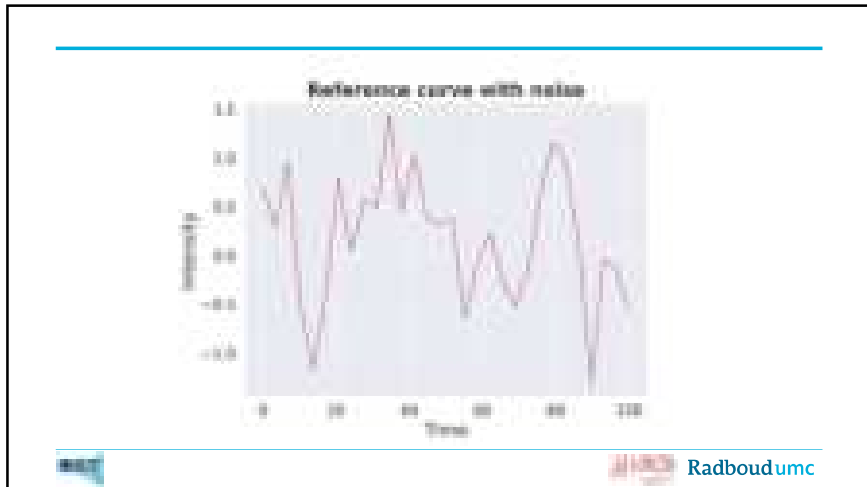
104



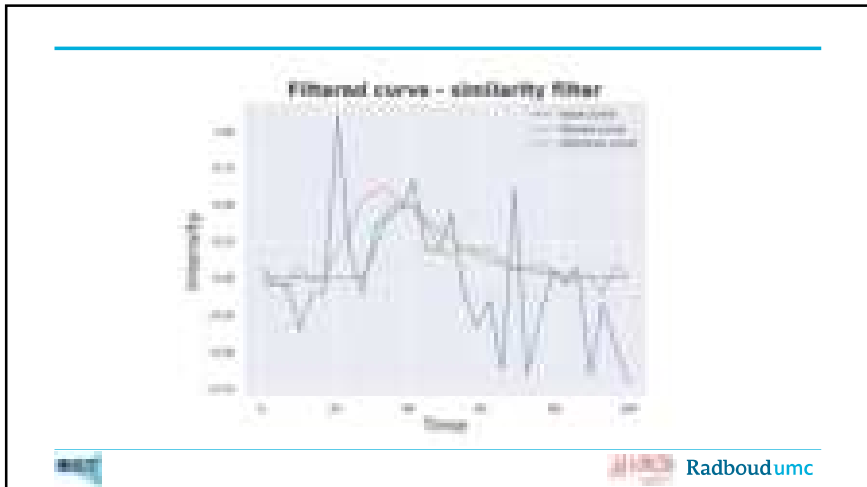
105



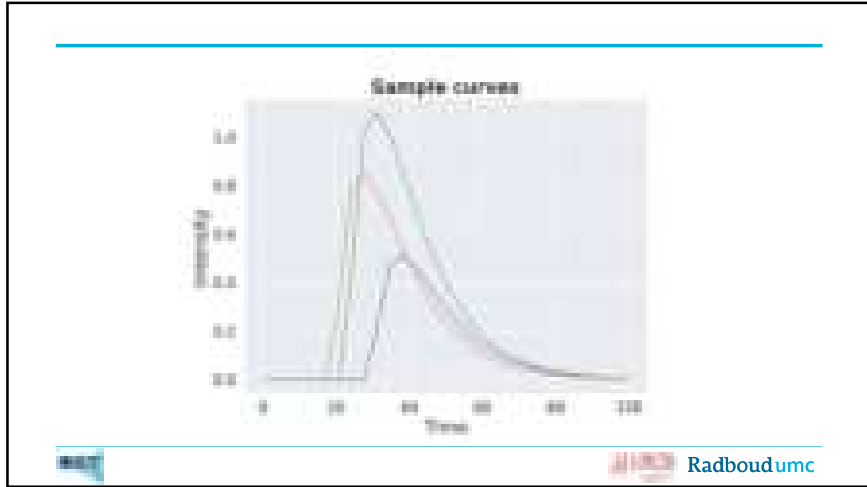
106



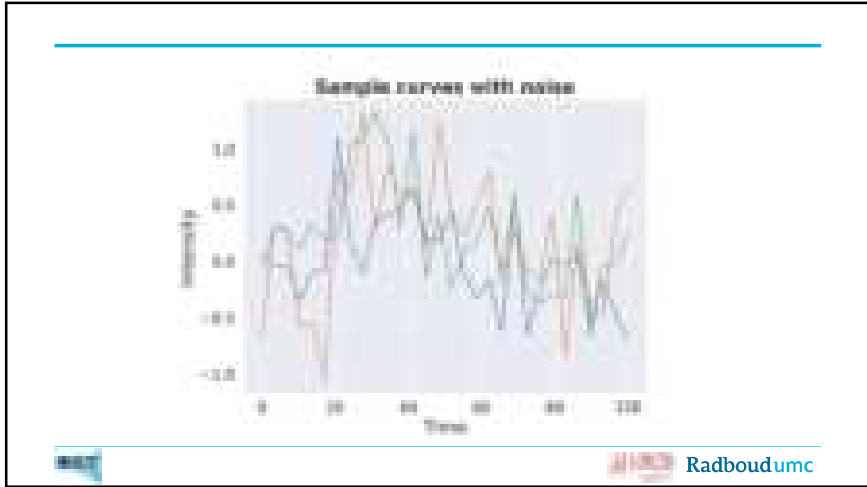
107



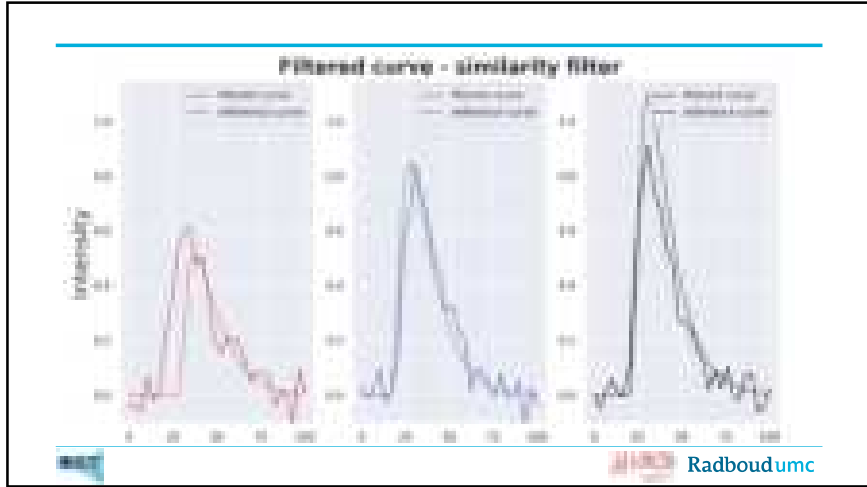
108



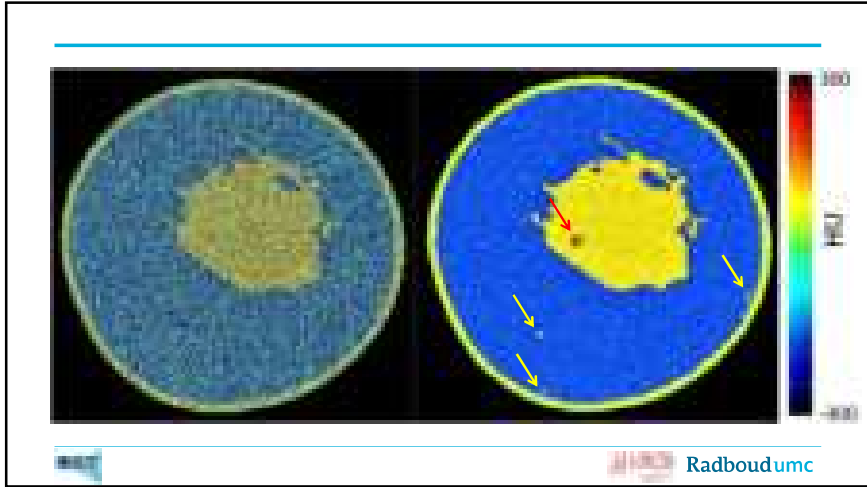
109



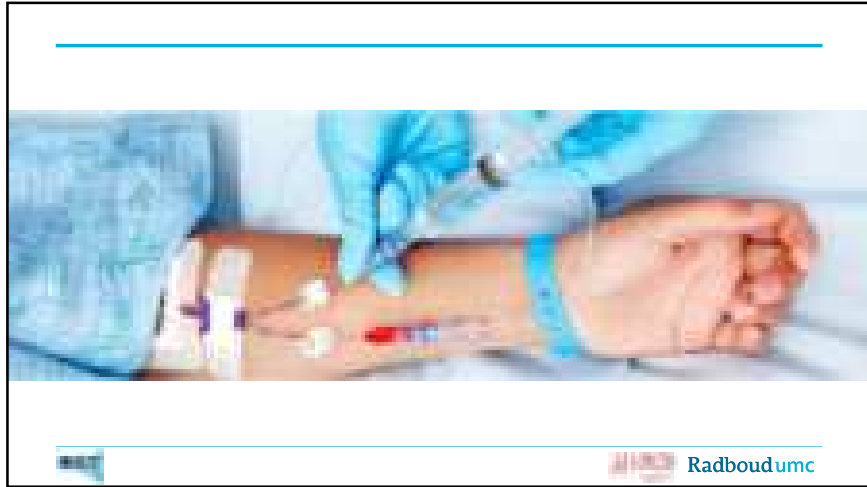
110



111



112



113

Up to 5 minutes scanning

Quantitative 4D characterization

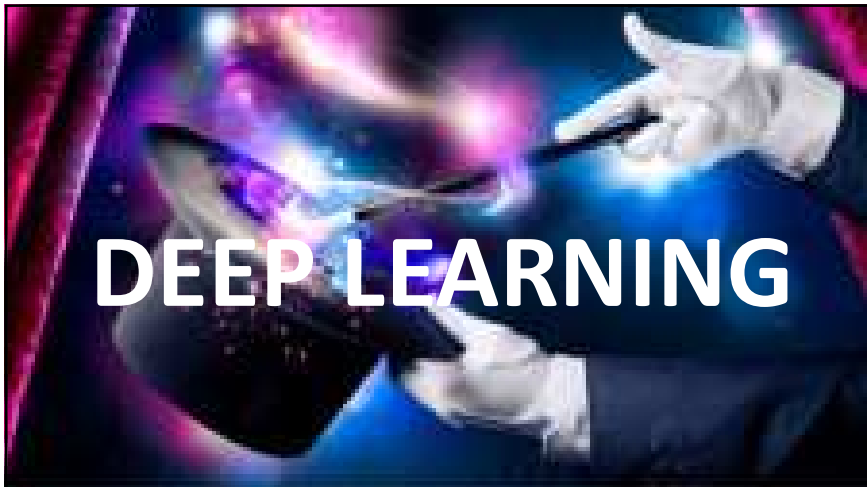 A slide containing two images. On the left is a grayscale medical scan showing a dark, curved, bowl-like shape. On the right is a smaller image showing a white peak on a black background, representing quantitative data.

114

Radiomic Analysis


 A slide showing a brain MRI scan on the left. To its right, a vertical list of four smaller images illustrates radiomic analysis: a color-coded heatmap, a white segmented mask, an orange heatmap, and a white peak on a black background.

115



116

## Cellular density

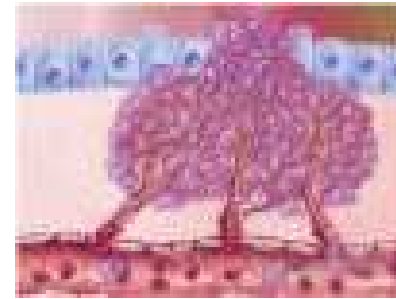


Wang et al, *PLoS ONE* 8(3): e58274.

Radboudumc

117

## Vascular Access




© Fairman

Radboudumc

118

## Molecular Profiles




Yezhelyev et al, *Advanced Materials*, 19: 3146–3151 (2007).

Radboudumc

119

## Genetic Characteristics

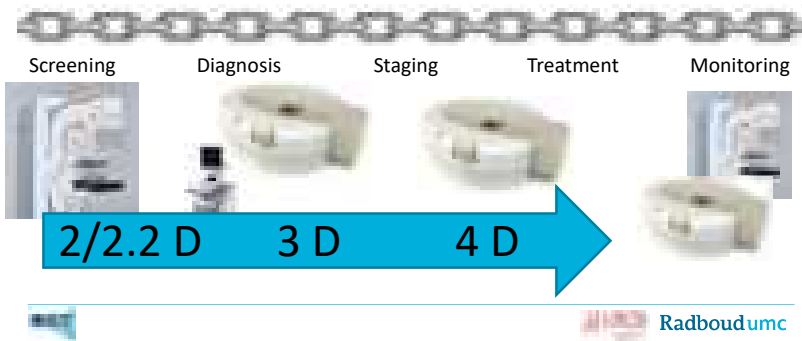


Bertucci et al, *Cancer Research*, 65(6): 2170–2178 (2005).

Radboudumc

120

## Imaging central to the entire breast cancer care chain



121

## Summary

Breast cancer care:

Screening  
Diagnosis  
Staging  
Treatment

122

## Summary

Screening:

2D - Digital mammography  
2.2D - Digital breast tomosynthesis  
+ AI(!)

123

## Summary

Diagnosis:

3D - Dedicated breast CT  
+ AI(!)

124

## Summary

Treatment planning/  
response prediction & monitoring:

4D – Dynamic perfusion breast CT  
+ AI(!)



125

# Thank you!

ioannis.sechopoulos  
@radboudumc.nl  
axti.radboudimaging.nl  
ioannisNL



126